



## **Fatty infiltration of the liver in a case of hypobetalipoproteinaemia with a novel mutation in the *APOB* gene**

Chris Florkowski, John Hedley, Vivienne Bickley, Amanda J Hooper, John R Burnett, Peter George

### **Case report**

A 63-year-old man was referred with abnormal liver function tests. ALT elevation had been documented for approximately 10 years and was 103 U/L with GGT of 103 U/L at the time of review. General health was good with no background of operations, transfusions, acupuncture or tattoos. He was a storeman by trade, a non smoker and alcohol consumption was modest. There was no family history of liver disease, although he was known to have low plasma cholesterol with his lowest documented level being 1.8 mmol/L with triglycerides 0.9 mmol/L, HDL-cholesterol 0.8 mmol/L, and a calculated LDL-cholesterol of 0.7 mmol/L.

Examination showed an overweight man, with body mass index of 28.3 kg/m<sup>2</sup> and blood pressure of 115/60 mmHg. There was no hepatosplenomegaly nor ascites and no stigmata of chronic liver disease. The rest of the examination was essentially normal.

Iron studies were normal apart from raised ferritin at 996 µg/L (reference interval 20-500), though *HFE* genotyping showed no mutations. He was negative for hepatitis A, B and C serologies and also smooth muscle antibodies. Plasma vitamin E was low at 16 µmol/L (reference interval 23-70). Abdominal ultrasonography confirmed fatty infiltration of the liver.

Western blotting (Figure 1) showed an abnormal apoB variant, approximately 80% of full-length apoB-100. The region of the *APOB* gene predicted to harbour the mutation was sequenced. This confirmed that the patient was heterozygous for a novel *APOB* mutation c.10312delA (p.Met3438X), predicted to cause a truncated apoB consisting of the amino-terminal 75.2% (apoB-75.2, 3410 amino acids out of 4536 in mature apoB).

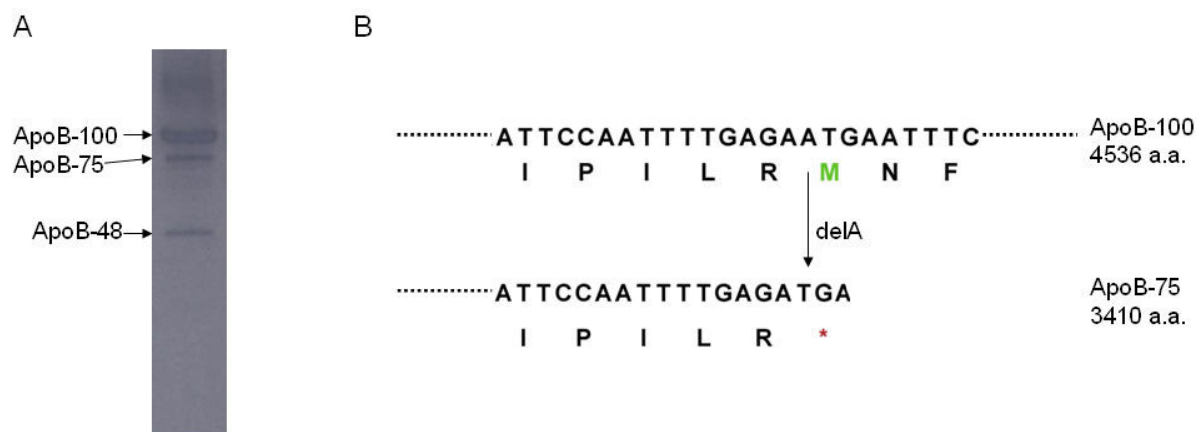
The patient thus had heterozygous familial hypobetalipoproteinaemia (FHBL), which is known to be associated with fatty infiltration of the liver.<sup>1</sup> He was placed on a fat restricted diet and given vitamin E supplementation.

### **Discussion**

Non-alcoholic fatty liver disease (NAFLD) is one of the most common liver diseases encountered in the developed world and refers to a spectrum of hepatic pathology that resembles alcoholic liver disease, but appears in individuals who have low or negligible alcohol consumption. It was initially recognised in morbidly obese females

with Type 2 diabetes, in whom the hepatic histology was consistent with alcoholic hepatitis, but there was no history of alcohol use.<sup>2</sup>

**Figure 1**



**Key:** Panel A shows separation of apoB-100, apoB-48 and the truncated apoB-75 variant in the index patient. Plasma proteins were separated by electrophoresis for 1.5 h at 150 V using a NuPAGE 3-8% Tris-acetate gel (Invitrogen). Proteins were transferred to nitrocellulose, and, after blocking, incubated with a monoclonal anti-apoB antibody (1D1, a kind gift from Dr Ross Milne, University of Ottawa Heart Institute) followed by sheep anti-mouse HRP-conjugated antibody (Millipore), and chemiluminescent detection (GE Healthcare). The region of the *APOB* gene predicted to harbour the mutation was sequenced. Panel B shows a representation of the wild-type and mutant alleles present in this patient, with deletion of A from native sequence (top line) resulting in the creation of TGA (bottom line), a premature stop codon.

More recently it has become apparent that NAFLD is a spectrum of disease and is probably the commonest cause of abnormal liver function tests in general practice.<sup>3</sup> Obesity, with insulin resistance is usually associated with the development of NAFLD and patients commonly exhibit hypertriglyceridaemia with low HDL cholesterol.<sup>4</sup> Fat accumulates in the liver when the rate of delivery of fatty acids to hepatocytes exceeds the metabolic capacity to process them.<sup>3</sup> Fatty acids are delivered to the liver from peripheral adipose tissue, and also from local synthesis in the liver as a result of either protein or carbohydrate excess.<sup>3</sup> Fatty acid disposal occurs through either mitochondrial beta-oxidation to ATP and ketone bodies, or secretion into the blood as triglycerides in very low-density lipoprotein (VLDL).

Disturbances in these processes can be inherited or acquired, resulting in the accumulation of triglycerides in the liver.<sup>3</sup> FHBL is a Mendelian co-dominant condition<sup>5</sup>, usually caused by truncation-producing mutations in the *APOB* gene. Truncations shorter than apoB-27 are not expressed in lipoproteins while those less than apoB-75 show little expression in LDL. The postulated mechanism of fat accumulation in the liver is decreased VLDL-triglyceride export, resulting from the defective assembly of lipoproteins containing truncated apoB<sup>1,7</sup>.

It has been shown that the smaller the apoB, the greater the decrease in hepatic secretion.<sup>8</sup> Other series have shown that approximately 50% of patients affected with this disorder have elevated transaminases, suggestive of fatty infiltration of the liver.<sup>6</sup> Low vitamin E was found in this case, as expected in one with very low LDL cholesterol and supplementation was given, although there are some data to suggest that tissue levels are not necessarily deficient.<sup>9</sup>

The association of NAFLD with very low cholesterol should prompt investigation for underlying FHBL, a recognised cause of NAFLD, as in our case, in which a novel mutation of the *APOB* gene was discovered.

**Authors:** Chris Florkowski, Consultant in Chemical Pathology, Canterbury Health Laboratories, Christchurch; John Hedley, Consultant Physician, Wairau Hospital, Blenheim; Vivienne Bickley, Scientific Officer, Molecular Pathology, Canterbury Health Laboratories, Christchurch; Amanda J Hooper, Senior Medical Scientist, Royal Perth Hospital, Perth, Western Australia; John R Burnett, Consultant Medical Biochemist and Clinical Lipidologist, Royal Perth Hospital, Perth, Western Australia; Peter George, Consultant in Chemical Pathology, Canterbury Health Laboratories, Christchurch

**Correspondence:** Dr Chris Florkowski, Chemical Pathologist and Diabetes Physician, Canterbury Health Laboratories, PO Box 151, Christchurch, New Zealand. Email: [ChrisF@cdhb.govt.nz](mailto:ChrisF@cdhb.govt.nz)

#### References:

1. Schonfeld G, Patterson BW, Yablonskiy DA, et al. Fatty liver in familial hypobetalipoproteinaemia: triglyceride assembly into VLDL particles is affected by the extent of hepatic steatosis. *J Lipid Res* 2003;44:470-478.
2. Ludwig J, Viggiano TR, McGill DB, Oh BJ. Nonalcoholic steatohepatitis: Mayo Clinic experiences with a hitherto unnamed disease. *Mayo Clin Proc* 1980;55:434-438.
3. Malnick SD, Beergabel M, Knobler H. Non-alcoholic fatty liver disease: a common manifestation of a metabolic disorder. *QJM* 2003;96:699-709.
4. Knobler H, Schattner A, Zhornicki T, et al. Fatty liver – an additional and treatable feature of the insulin resistance syndrome. *QJM* 1999;92:73–79.
5. Whitfield AJ, Barrett PHR, van Bockxmeer FM, Burnett JR. Lipid disorders and mutations in the *APOB* gene. *Clin Chem* 2004;50:1725-1732.
6. Whitfield AJ, Marais AD, Robertson K, et al. Four novel mutations in *APOB* causing heterozygous and homozygous familial hypobetalipoproteinaemia. *Hum Mutat* 2003;22:178.
7. Elias N., Patterson BW, Schonfeld G. Decreased production rates of VLDL triglycerides and ApoB-100 in subjects heterozygous for familial hypobetalipoproteinemia. *Arterioscler Thromb Vasc Biol* 1999;19:2714-2721.
8. Parhofer KG, Barrett PHR, Aguilar-Salinas CA, Schonfeld G. Positive linear correlation between the length of truncated apolipoprotein B and its secretion rate: in vivo studies in human apoB-89, apoB-75, apoB-54.8, and apoB-31 heterozygotes. *J Lipid Res* 1996;37:844-852.
9. Clarke MW, Hooper AJ, Headlam HA, et al. Assessment of tocopherol metabolism and oxidative stress in familial hypobetalipoproteinemia. *Clin Chem* 2006;52(7):1339-45.